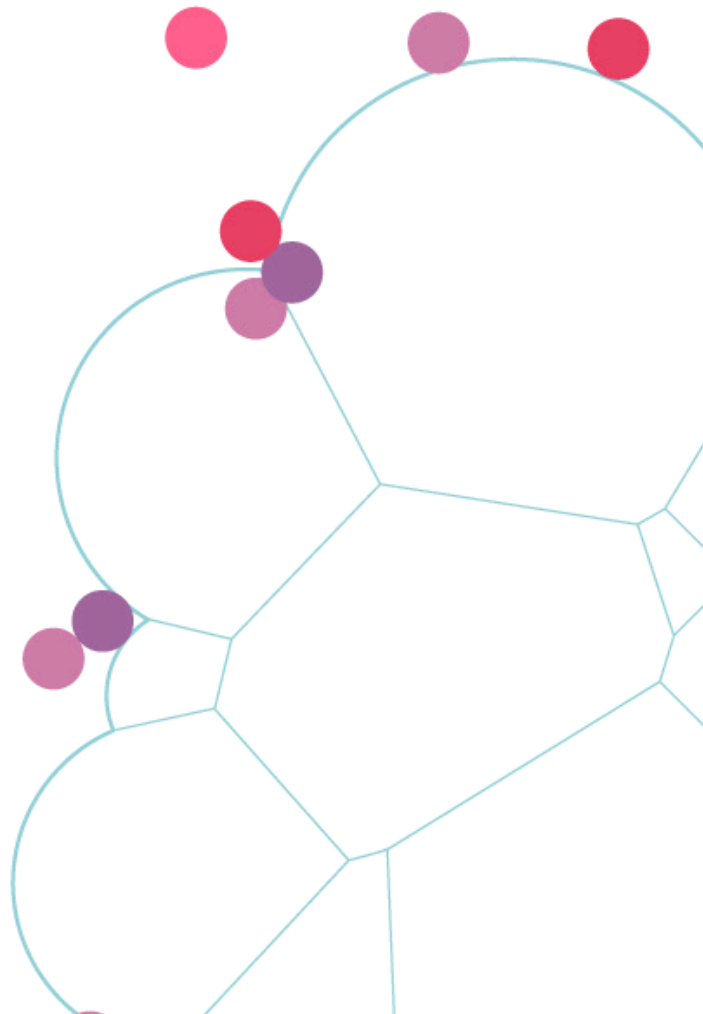


Case Study

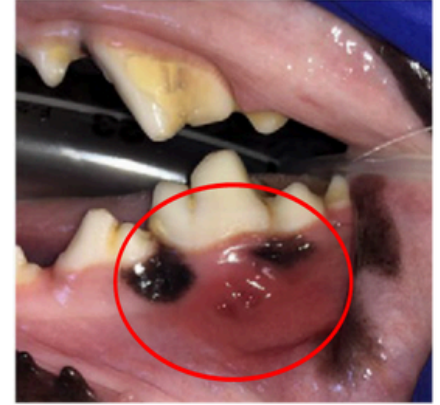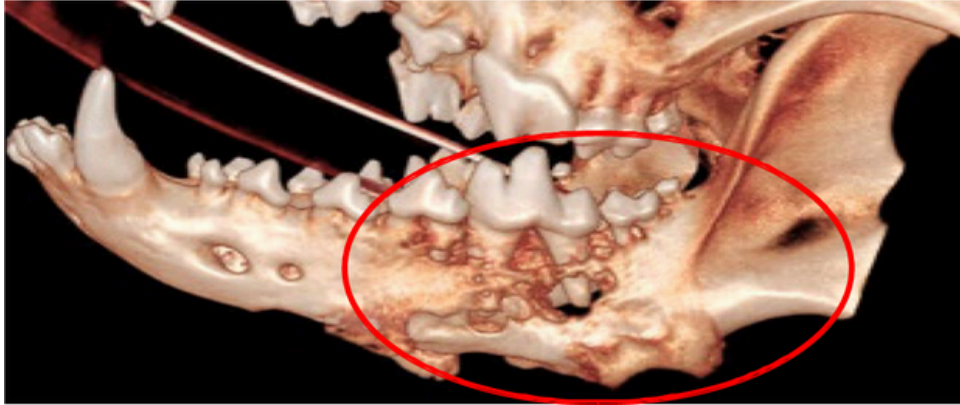**Bone line restoration in 2.5Y old
English Sheepdog/Poodle mix**



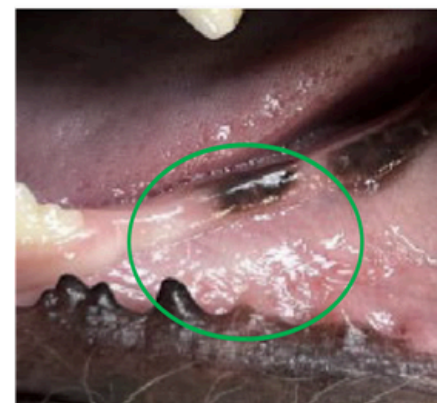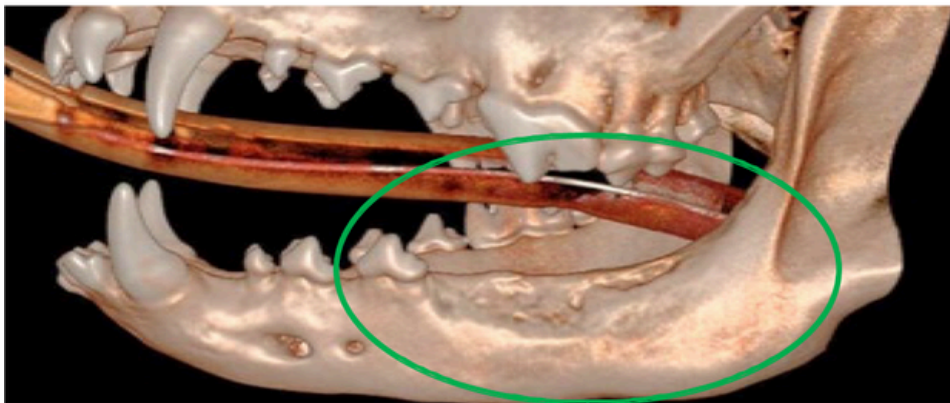
Dr. Jen Mathis, DVM
DAVDC Board Certified
Veterinary Dentist and Oral
Surgeon



Before



After



**4 months follow up: 2.5Y old English Sheepdog/Poodle mix
DVM Jennifer Mathis**