

Case Study

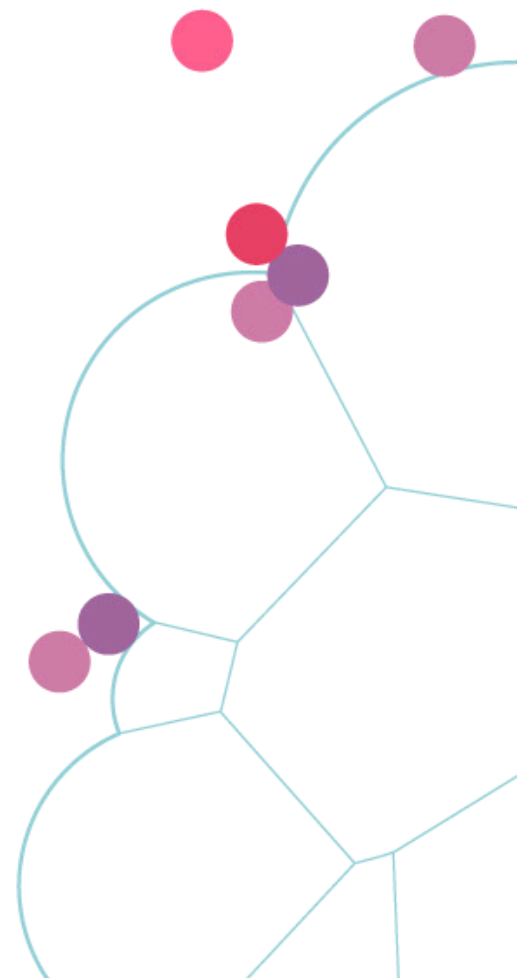Mandibular fracture healing

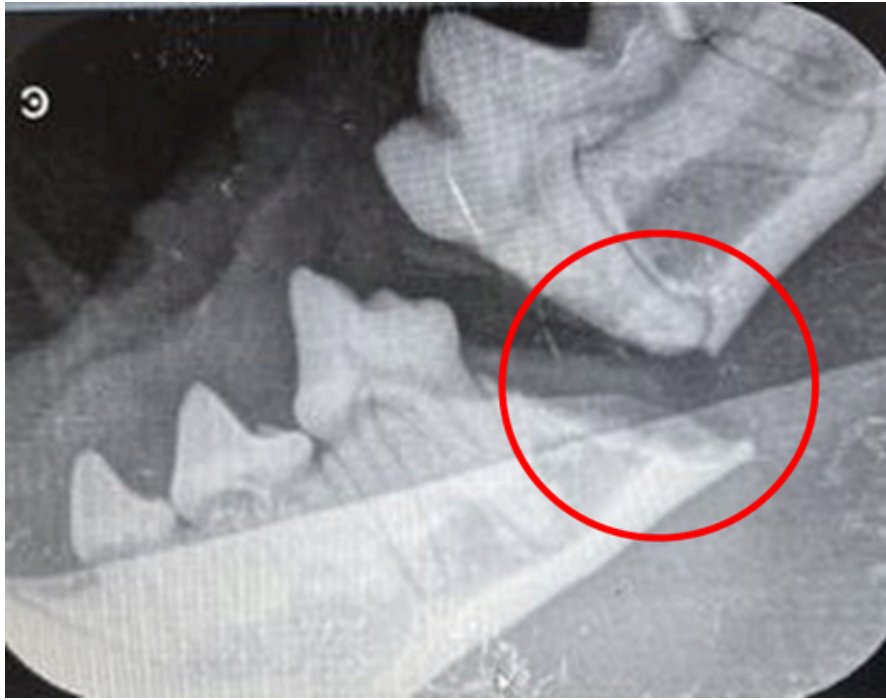


**Yoav Bar Am DVM,
Dip. AVDC, Dip.
EVDC & Yael Bar Giora
DVM, Israel (Dec2023)**

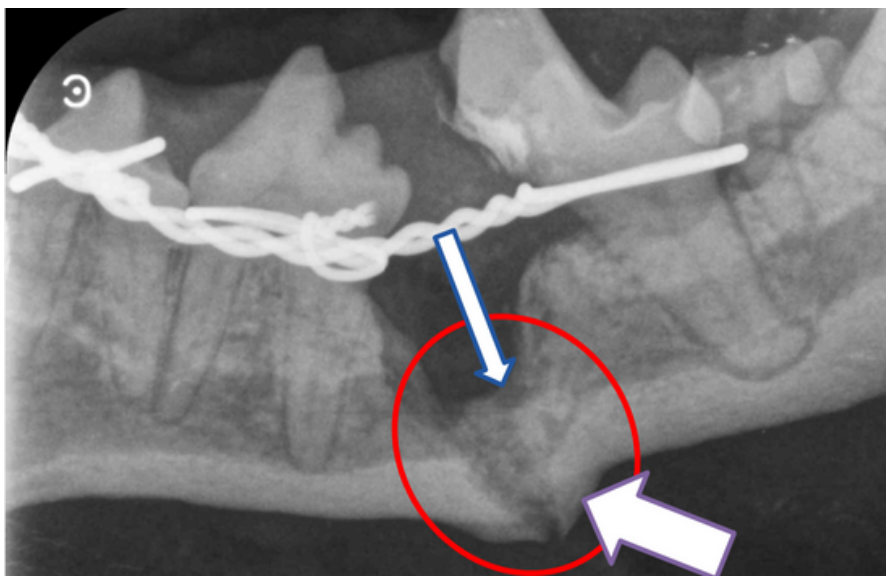


**DR. Yael Bar Giora
DVM**

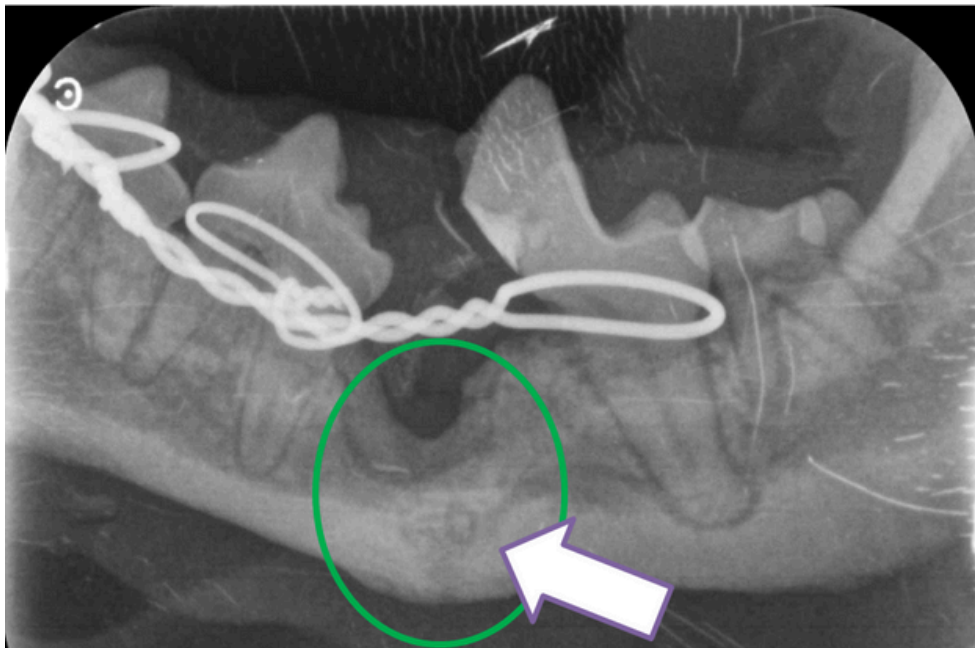




A case that could not heal for 9 weeks, after using ReGumTMVet, the Shih Tzu's jaw healed after 8 weeks only.
Yoav Bar Am DVM, Dip. AVDC, Dip. EVDC & Yael Bar Giora DVM, Israel (Dec2023)



**9 weeks with fixation only:
Poor/no union
Scaffold was applied at this visit**



**8 weeks after applying ReGumTMVet:
Mandibular fracture was healed**